



TO THE RESULT OF IMPROVED DIAGNOSIS AND TREATMENT OF CEREBELLAR TUMORS

¹Shodiev Amirkul Shodievich

²Norkulov Najmiddin Uralovich

³Ravshanov Davron Mavlonovich

¹Samarkand State Medical University

ANNOTATION

The data of complex investigation and treatment of 37 (21 women, 16 men) patients, the average age of the patients composed 30 years (from 5 till 76 years) are included in the present research. Complex investigation was applied for all patients, including brain CT, MRI and contrast CT, MRI. Postoperative mortality was observed in 5 (13.5%) patients, and it is dominated after subtotal removal of the tumor, but there was not registered results in patients after total removal of the tumor and biopsy death. Results of treatment of cerebellar tumors depend on application of modern surgical methods and their efficacy.

Key words: cerebellar tumors, medulloblastoma, hemisphere, astrocytoma, ependymoma.

Relevance

The relevance of diagnosis and treatment of cerebellar tumors is due to the prevalence of these pathologies, the severity of the course, and the insufficient effectiveness of common methods of surgical treatment. Among neurooncological diseases in children, cerebellar tumors range from 70.6 to 73.6%, according to the histological structure of them, medulloblastomas range from 29.0% to 48.9%, astrocytomas from 32.1% to 36.0%, ependymomas from 1.4% to 18.0% [1,9,14,18,21].

The severity of the course and the severity of the prognosis in patients with cerebellar tumors are due to the development of hydrocephalic-hypertensive and dislocation syndromes. The development of hydrocephalus in the localization of the tumor in the cerebellum is more common than in other localizations and is due to occlusion of the CSF pathways [3,5,7,8,19,22].

Neuroimaging methods such as computed tomography (CT) and especially magnetic resonance imaging (MRI) have made a major breakthrough in the non-invasive study of the localization and structure of brain tumors, patterns of their growth and blood supply, relationships with surrounding tissues, dynamics of their development [2,4,10,12,15,17].





Surgical tactics consist, if possible, in the radical removal of the tumor, followed by the restoration of CSF circulation. With the help of liquor shunting operations, although it is possible to achieve control over hydrocephalus, however, after these operations, in 70-95% of cases, the condition of patients becomes drainage-dependent and 1/3 of patients develop certain complications [5,6,11,13,16,20] .

The study of the results of using various diagnostic and treatment approaches helps to determine the effectiveness of existing methods for diagnosing and treating cerebellar tumors.

Purpose of the study. The aim of our study was to study the issues of improving the diagnosis and treatment of cerebellar tumors.

Materials and research methods. The present study included data from a comprehensive examination and treatment of 37 (21 women, 16 men) patients. The average age of the patients was 30 years (from 5 to 76 years) who were hospitalized in the neurosurgery department of the clinic of the Samarkand Medical Institute for cerebellar tumors from 2018 to 2021 . All patients underwent a comprehensive examination, including conventional and contrast-enhanced CT scans, MRI studies of the brain.

Results of the study and their discussion. To diagnose tumors of the cerebellum, all (100.0%) patients underwent MRI and CT, and contrast MRI of the brain (29.7 %) patients. The CT and MRI picture, depending on the structure of the tumor itself, was cystic in 14 (37.8 %) , solid in 5 (13.5 %) , cystic-solid in 6 (16.2 %) and cystic -solid in 12 (32) . , 4 %) infiltrative (Fig.1) .

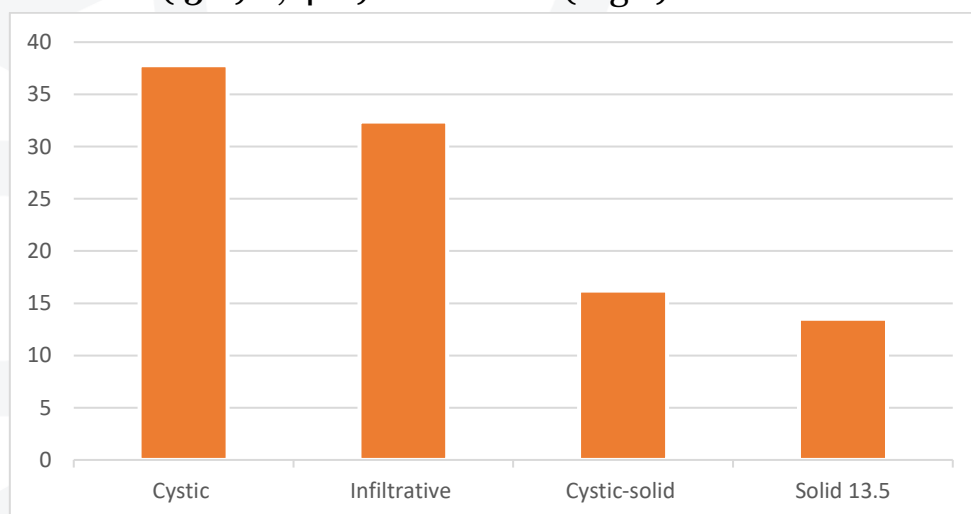


Fig.1 Distribution of cerebellar tumors depending on the structure



According to localization, in 15 (40.5 %) patients it was localized in the hemispheres, in 10 (27.0 %) patients in the cerebellar vermis, in 8 (21.6 %) patients in the cerebellopontine angle, in 4 (10.8 %) of the patient in the IV ventricle (Fig. 2) .

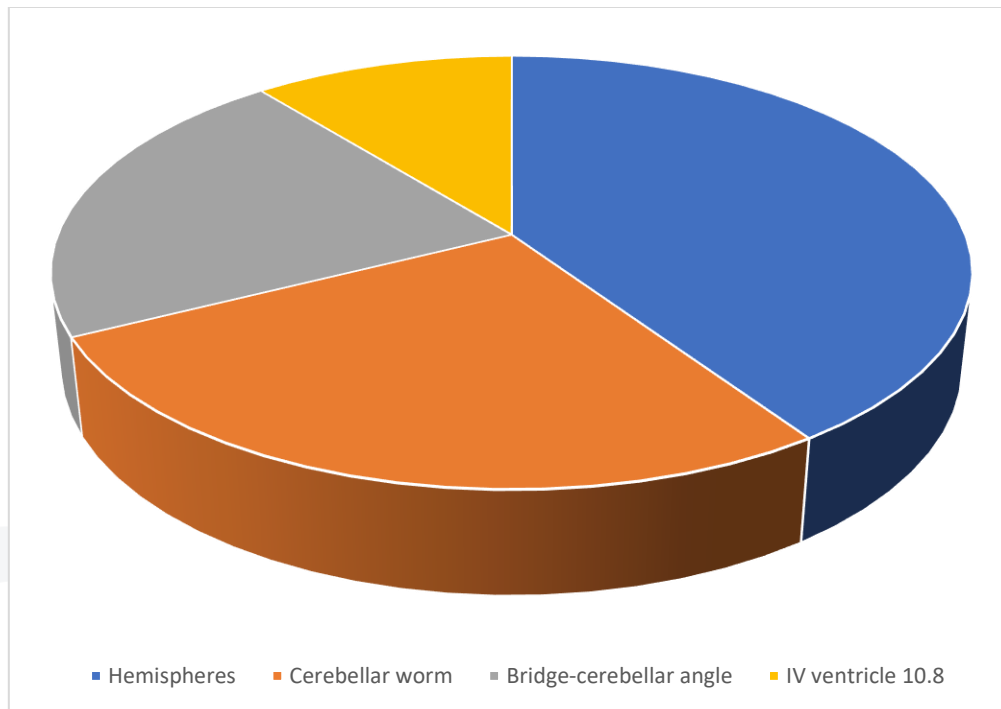


Fig. 2 Localization of cerebellar tumors

All patients underwent surgical treatment, the essence of which was as radical removal of the tumor as possible, depending on the operability of the tumor itself, followed by restoration of CSF circulation.

Taking into account the localization of cerebellar tumors, we used the following surgical approaches: in 23 (62.2 %) patients, a median skin incision and resection of the occipital bone scales, in 14 (37.8 %) patients, a paramedian skin incision on the left or right with resection of the occipital bone . Of the 37 patients, 17 patients (45.9 %) underwent Thorkildsen ventriculocisternostomy in order to normalize CSF flow . Histological examination of patients with cerebellar tumors most often revealed medulloblastomas (42.9%), followed by astrocytomas (37.1%) and ependymomas in 20.0% (Fig. 3).

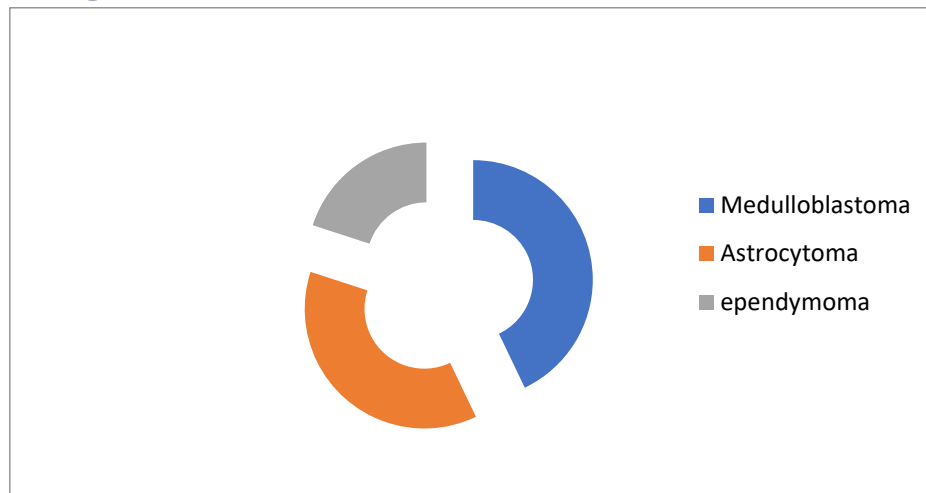


Fig.3 Histological structure of cerebellar tumors

It should be noted that out of 37 operated patients, total tumor resection was achieved in 27 (73.0 %), subtotal resection in 8 (21.6 %), and biopsy was performed in 2 (5.4 %) patients .

Postoperative lethality was noted in 5 (13.5 %) patients, and it was noted only among patients who underwent subtotal tumor resection, and in patients after total tumor resection and biopsy, no lethal outcome was noted .

Conclusions:

1. Improving the results of diagnosing cerebellar tumors is due to the use of modern diagnostic methods (magnetic resonance and computed tomography methods) studies that allow determining structures, morphological features, the presence of infiltration, cysts and edema with their qualitative and quantitative assessment. the cerebellum are cystic (37.8%), infiltrative (32.4 %), cystic-solid (16.2 %) and solid (13.5 %) tumors are relatively less common. These tumors are predominantly localized in the hemispheres (40.5%), the vermis (27.0%), then in the cerebellopontine angle (21.6%) and the IV ventricle (10.8%). Among tumors of the cerebellum, medulloblastomas predominate (42.9%), followed by astrocytomas (37.1%) and epindymomas (20.0%).
3. The results of surgical treatment of cerebellar tumors depend on the use of modern microsurgical methods and their radical nature.



BIBLIOGRAPHY:

1. Anan'eva I.I., Malkarov M.S., Korsakova N.A., Balkonov A.S., Dorofeev A.E., Kachkoe I.A., Suchkov S.V. Glial brain tumors: modern aspects of classification and the basis of genetic predisposition // Archives of Pathology. 2007. V. 69. No. 1. S. 54-60.
2. Gorelyshev S.K. Tumors of the chiasm and the bottom of the third ventricle: Abstract of the thesis. dis. Dr. med. Sciences. M 2004.
3. Kim A. V. Diagnosis and treatment of hydrocephalic-hypertensive syndrome in children with tumors of the posterior cranial fossa, diss. PhD, 2004.
5. Konovalov A.N., Kornienko V.N., Ozerova V.I., Pronin I.N. Neuroradiology of childhood. M: Antidor 2001.
6. Norkulov S.N., Shodiev A.Sh., Mamadaliev A.M., Norkulov N.U. On the features of the diagnosis and treatment of cerebellar tumors // Problems of biology and medicine, No. 2 (83), Pp. 79-82, 2015, Samarkand.
7. Shcherbenko O.I. Ependymomas of the brain. The current state of the issue. Literature review // Bulletin of the Russian Scientific Center for Roentgen Radiology of the Federal Agency for High-Tech Medical Care. 2012. V. 2. No. 12. S. 14-14.
8. Shchigolev Yu.S., Gizatullin Sh.Kh., Sidorenko V.V., Smorodsky S.G. Metastatic tumors of the nervous system // Military medical journal. 2006. V. 327. No. 6. S. 30-34.
9. Gaidar, B. V. Radiation diagnosis of tumors of the brain and spinal cord / B. V. Gaidar [et al.]. St. Petersburg: Foliant Publishing LLC, 2006. 336 p.
10. Lectures on neurosurgery / ed. V. E. Parfenova, D. V. Svistova. St. Petersburg: Foliant Publishing LLC, 2004. 336 p.
11. Practical neurosurgery: hands. for doctors / ed. B. V. Gaidar. St. Petersburg: Hippocrates, 2002. 648 p.
12. Smeyanovich, A. F. Diagnosis and surgical treatment of subtentorial peristern meningiomas / A. F. Smeyanovich, Yu. G. Shanko. Minchik: Minsktiprproekt, 2005. 108 p.
13. Oncology: national guidelines / ed. Chissova V.I., Davydova M.I. — M.: GEOTAR-Media, 2008.
14. Pashkov A.A. Facial and headaches. Vitebsk: EE "VGMU", 2010. - 48 p.
15. Mukhacheva M.V., Bein B.N., Shishkina E.S. Clinical features of the epileptic syndrome in patients with brain tumors // Medical Almanac, 2016.
16. Sorokin Yu.N., Usatov S.A., Kovalenko A.P. Symptoms of early clinical manifestations of brain neoplasms // Emergency Medicine, 2013.



17. *Shain A. A. ONCOLOGY. Textbook for medical students. - Medical Information Agency, 2004. - 544 p.*
18. *McTyre E., Scott J., Chinnaiyan P. Whole brain radiotherapy for brain metastasis. Surgical Neurology International. 2013;4(Suppl 4): p236-244.*
19. *Bruns DE, Ashwood ER, Burtis CA (eds.). Fundamentals of Molecular Diagnostics. St. Louis: Saunders 2007.*
20. *Ling Weiwang, Cheng Ying Shiau, Wen Yuh Chung . Gamma Knife surgery for low-grade astrocytomas: evaluation of long-term outcome based on a 10-year experience. J Neurosurg 2006; 105: Suppl: 127-132.*
21. *Louis DN, Ohgaki H., Wiestler OD, Cavenee WK., Burger PC., Jouvet A., Scheithauer BW, Kleihues P. The 2007 WHO Classification of Tumors of the Central Nervous System. Acta Neuropathol 2007; 114(2): 97-109.*
22. *Chemotherapy, radiation therapy combination improves outcomes for people with low-grade brain cancer Published on March 10, 2015*